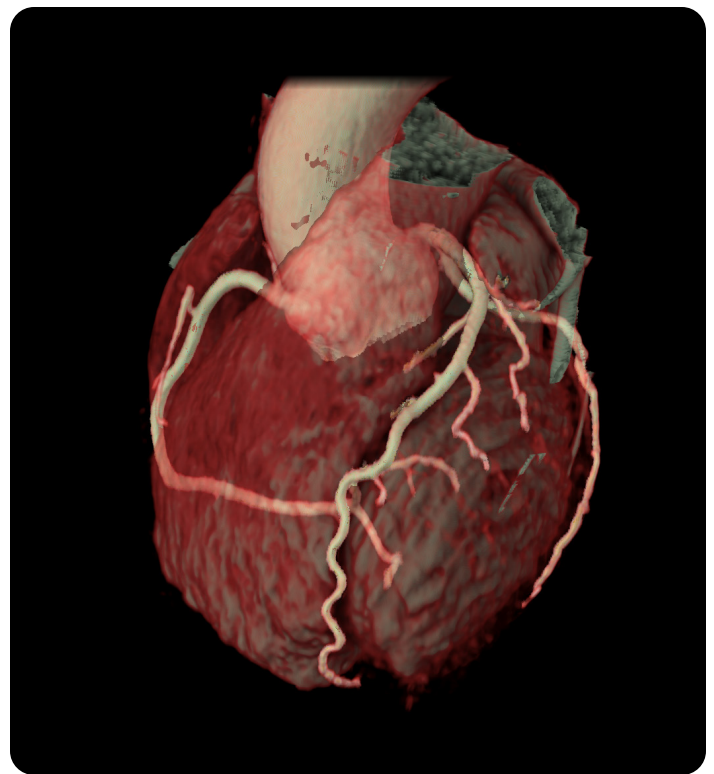


Unlocking the potential of ECG-less Cardiac in emergency radiology

Universitair Ziekenhuis Brussel is one of Belgium's premier Centres of Excellence in healthcare, biomedical research and medical education. As a top-rated hospital, UZ Brussel has gained recognition at both a national and an international level. UZ Brussel clinicians care for nearly 30,000 inpatients and 500,000 outpatients every year. The hospital's emergency radiology department (ED) implemented ECG-less Cardiac from GE HealthCare, a groundbreaking solution for challenging cardiac CT examinations without an ECG signal. This helps the highly specialized radiographer team manage increased complexity and time sensitivity in examining critical patients, which is exacerbated by the challenge of maintaining adequate staffing levels amid shortages. This case study summarizes the early results of ECG-less Cardiac at UZ hospital.

Cardiac CT imaging

Cardiac computed tomography (CT) is a non-invasive imaging modality increasingly used in emergency settings to rapidly evaluate patients with chest pain and other symptoms suggestive of acute coronary syndrome (ACS). Cardiac CT scans traditionally rely on ECG signals to synchronize image acquisition with the cardiac cycle to deliver high-quality, accurate images with reduced radiation dose. However, ECG signals might not be accessible in some situations, leading to scan failure and degraded image quality. At UZB, this issue is particularly prevalent in patients who arrive to the CT suite with diagnostic ECG and other monitors already attached, when an ECG signal is not accessible, or in critical patients who require a fast cardiac evaluation.



The hospital needed a solution that delivered high-quality cardiac CT scans for all patients, especially for emergency patients, regardless of ECG signals.

Introducing ECG-less cardiac

UZ Brussel implemented ECG-less Cardiac from GE HealthCare, a groundbreaking solution for challenging CT examinations, in its emergency radiology department (ED). ECG-less Cardiac facilitates imaging complicated inpatients or ED patients who arrive with diagnostic ECG and other monitors attached, or when the ECG signal is not available due to signal interference. It's also ideal for acute patients who need rapid cardiac evaluation.

With ECG-less Cardiac, clinicians have the flexibility to acquire scans of different durations, from a single rotation to a full cycle. It allows clinicians to meet the clinical needs for dose, image quality and cardiovascular function without the patient's ECG signal, while generating diagnostic-quality images for coronary and functional assessment. It also addresses workflow challenges associated with patient preparation, including prepping the skin, attaching ECG patches and grounding straps, doing an impedance check, and ensuring the ECG trace is displayed on the operator console – all of which adds to the overall exam time.

It leverages the Revolution Apex™ Elite CT system's 160mm coverage, 0.23sec gantry rotation speed, SmartPhase automatic cardiac phase selection, and SnapShot Freeze 2 (SSF2) whole-heart motion correction to acquire diagnostic-quality images without an ECG signal, using a reasonable estimate of the patient's heart rate provided by the user prior to the scan.

Technology enablers

160mm

The 160mm Clarity Detector's z-coverage makes whole-heart coverage in a single axial rotation a reality. This hardware breakthrough eliminates the step-stair artifact, which is reported to occur in up to 18% of patients and 77% of coronary segments in different CT scanners with narrow detectors.

0.23sec

Temporal resolution is a critical factor in cardiac CT imaging because it determines the ability to freeze the motion of the beating heart, thus reducing motion artifacts and improving image clarity. Revolution Apex Elite delivers 19.5msec effective cardiac temporal resolution, enabled by the fastest 0.23s gantry rotation and SnapShot Freeze 2 (SSF2) whole-heart motion-correction algorithm.

Snapshot Freeze 2

Snapshot Freeze 2 intelligent motion correction algorithm, designed for coronary and valve motion correction, chambers, myocardium correction, great vessels motion correction.

Smart Phase

Smart Phase is a reconstruction feature designed to intelligently select the best cardiac phase for image reconstruction. This ensures improved image quality with the least motion and enhances workflow by reducing the need for manual phase adjustments.

Excellent image quality and streamlined workflow

ECG-less Cardiac helps UZ Brussel clinicians address challenging cardiac exams where patient access and speed are critical, resulting in improved cardiac assessments and workflow for critical clinical presentations.

Hans Nieboer, MD, FASER, FESER, is an emergency radiologist at UZ Brussel who has used ECG-less Cardiac for his ED patients in combination with CT angiography (CTA).

“It can be useful in cases of acute chest pain where there is a broad differential diagnosis. We’re investigating how to use it when we need to quickly rule out conditions using CTA for pulmonary embolism or aortic dissection, or to evaluate the coronary arteries to exclude an acute coronary syndrome without the need for ECG leads.”



Koenraad (Hans) Nieboer
MD, FASER, FESER
Head of Emergency Radiology
University Hospital Brussels,
Belgium

He said ECG-less Cardiac differs from traditional cardiac imaging methods, with unique advantages that could have an impact on diagnoses.


“If we can combine this technology with routine pulmonary embolism studies, it would save a significant amount of time by eliminating the need to attach ECG leads and find the optimal ECG signal. This would allow us to optimize diagnostics without any time loss. Theoretically, this approach could also be applied in cases of acute thoracic trauma and acute stroke imaging.”

ECG-less Cardiac has helped the ED improve workflow and efficiency, while streamlining the diagnostic process over traditional methods.

“You don’t need to prepare the patient (such as shaving their chest hair), attach leads, search for an optimal signal or perform an impedance test. We also save time by not needing to record an ECG. SmartPhase and SSF2 ensure optimal quality, which is crucial in an acute context. We only need to input the average heart rate, which is easy.”

UZ Brussel emergency CT technologist Ineke Van Haelst agreed that ECG-less Cardiac is a user-friendly process that offers a streamlined approach to cardiac CT scanning, giving her extra time to focus on the patient. Adding an ECG-less acquisition to a CTA requires no additional effort, and it can be performed with the same contrast bolus.

“It doesn’t involve much extra work; it’s smooth and quick, with less time spent on wiring (ECG). We can monitor the heart rate without touching the patient, just by entering the average heart rate. Compared to a standard cardiac examination, we save a lot of time. I used to think cardiac examinations would be complex, but they are not at all.”



Ineke Van Haelst
Technologist Emergency CT

Excellent image quality and streamlined workflow (cont.)

The patient arrived in the emergency ward with chest pain and a suspicion of aortic dissection. The patient was immediately taken to the CT and monitored to keep checking vital parameters.

Since there was no time to connect ECG leads, the technician selected the ECG-less protocol to scan the heart and total aorta with one bolus.

ECG-less CCTA – 100 kV – 3/4 cycle – Free breathing – BPM 80

ECG-Less Cardiac	
Rotation time, s	0.23
BPM	80
Slice, mm	0.625
kV	100
mA	325
One bolus Contrast	
ml	80
mg/ml	350
CTDi, mGy	1.9
DLP, mGy-cm	137

Findings: Aorta dissection

HyperDrive Aorta at 523mm/s acquisition speed – 100 kV – Free breathing – BPM 80

DLIR – Lung-M

DLIR – Lung-M

HyperDrive	
Rotation time, s	0.23
BPM	80
Slice, mm	0.625
kV	100
mA	211/396
CTDi, mGy	9
DLP, mGy-cm	144

Findings: Aorta dissection

The studies varied by clinical indications, study protocols and comparison methods. The results and conclusions obtained in these studies are applicable to the specific studies cited and may not be generalizable or reproducible in every practice.

